



# EDUCATIONAL PPT FOR SURGICAL ANATOMY OF SPINAL CORD FOR LUMBAR PUNCTURE PROCEDURE

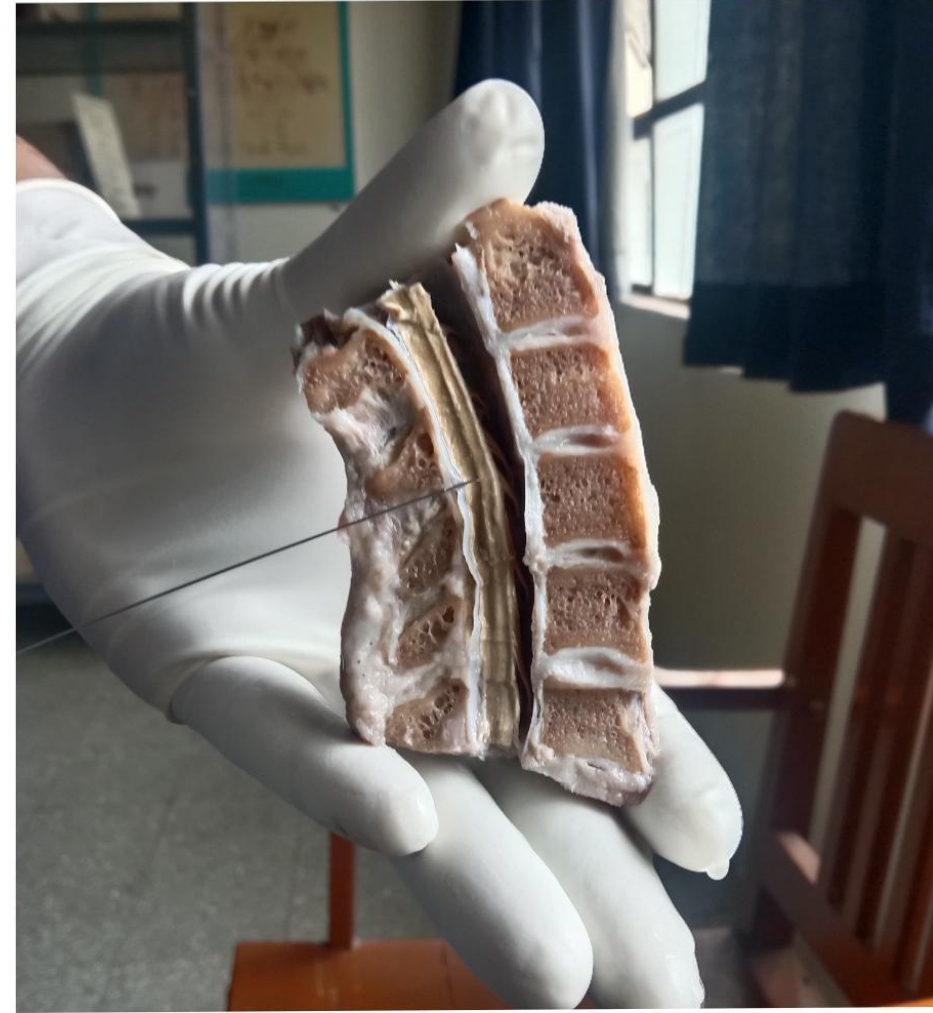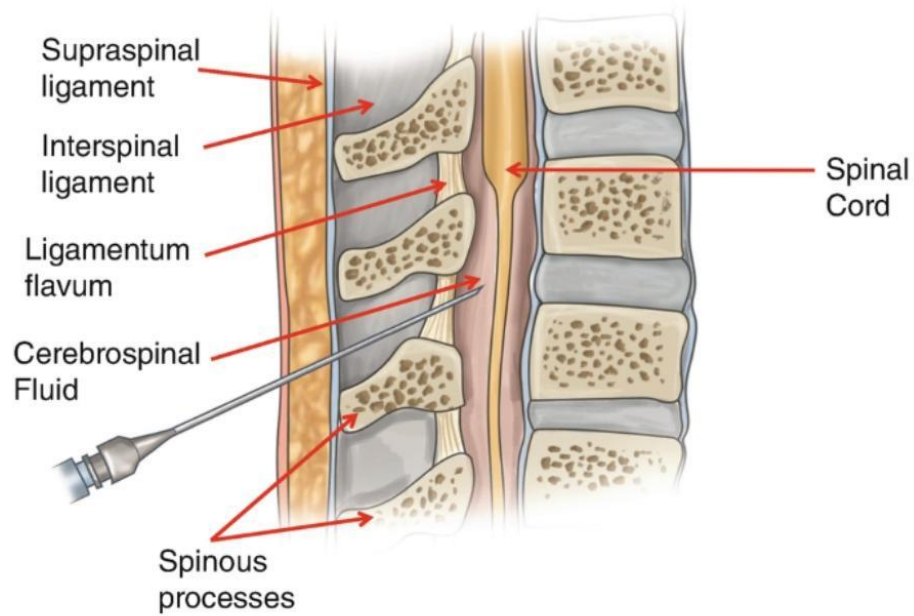
Dr.Kamalakar V Gajare sir  
(Guide and HOD,shalyatantra dept,SSAM Hadapsar,Pune)

Dr Niranjan D Dusane  
(1st yr PG scholar-shalyatantra)

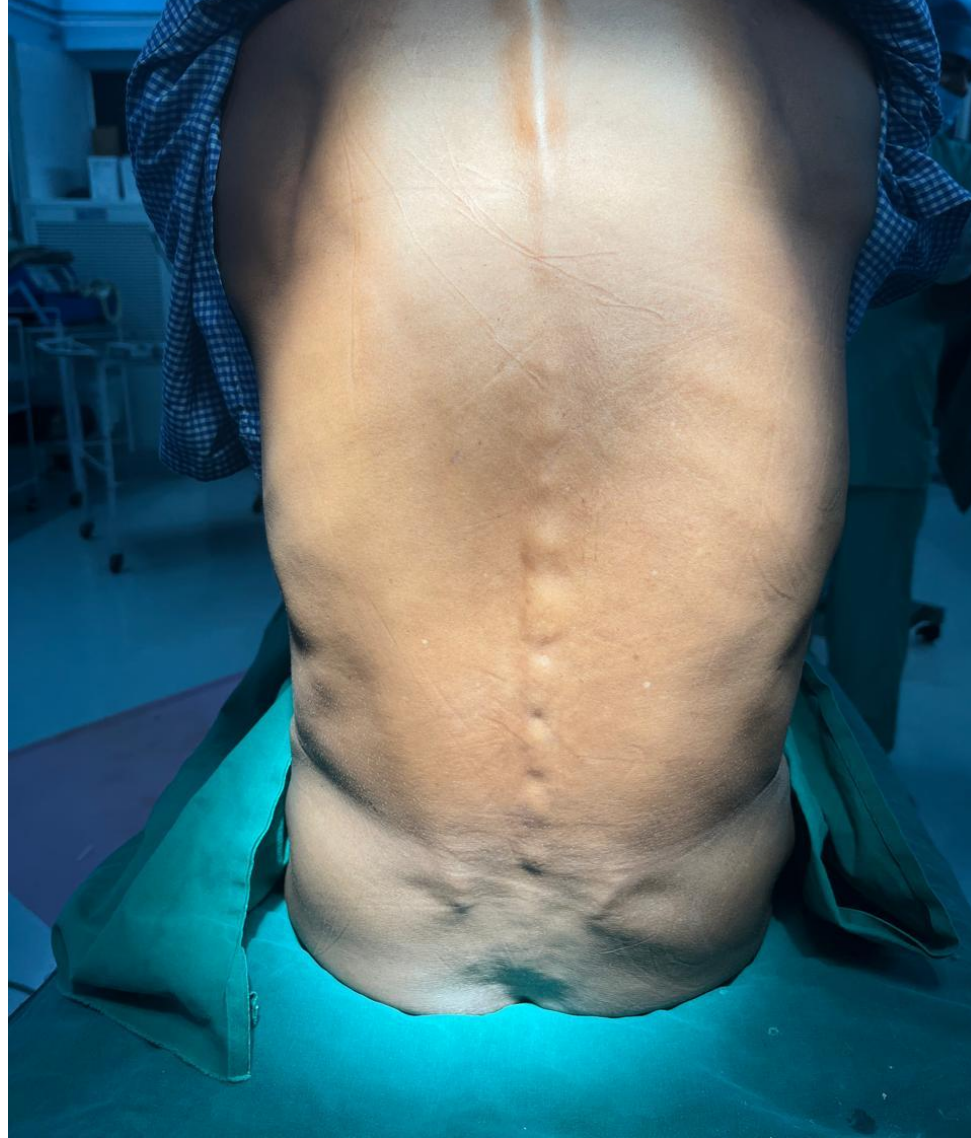


Under the guidance of  
Hon. Dr. Milind Joshi sir  
(Consulting Anaesthesiologist and intensivist)

With the support from  
Dr. Nilesh Phule sir  
(Prof and HOD department of Rachana Sharir)



# VERTEBRAL COLUMN



MAM's Sumatibhai Shah Ayurved Mahavidyalaya, Hadapsar



# LAYERS ENCOUNTERED WHILE LUMBAR PUNCTURE

1. Skin
2. Subcutaneous tissue
3. Supraspinous ligament
4. Interspinous ligament
5. Ligamentum flavum
6. Subdural space
7. Dura matter
8. Sub arachnoid space
9. Arachnoid

# PROCEDURE OF LUMBAR PUNCTURE



-Explain the procedure to the patient and get informed consent

Position for lumbar puncture

-1)seating position

2)lateral decubitus position

-Cleanse skin with povidine iodine 10% from puncture site to radially outwards

-cleanse skin with spirit and allow to dry

Drape below patient and around site with fenestrated drape

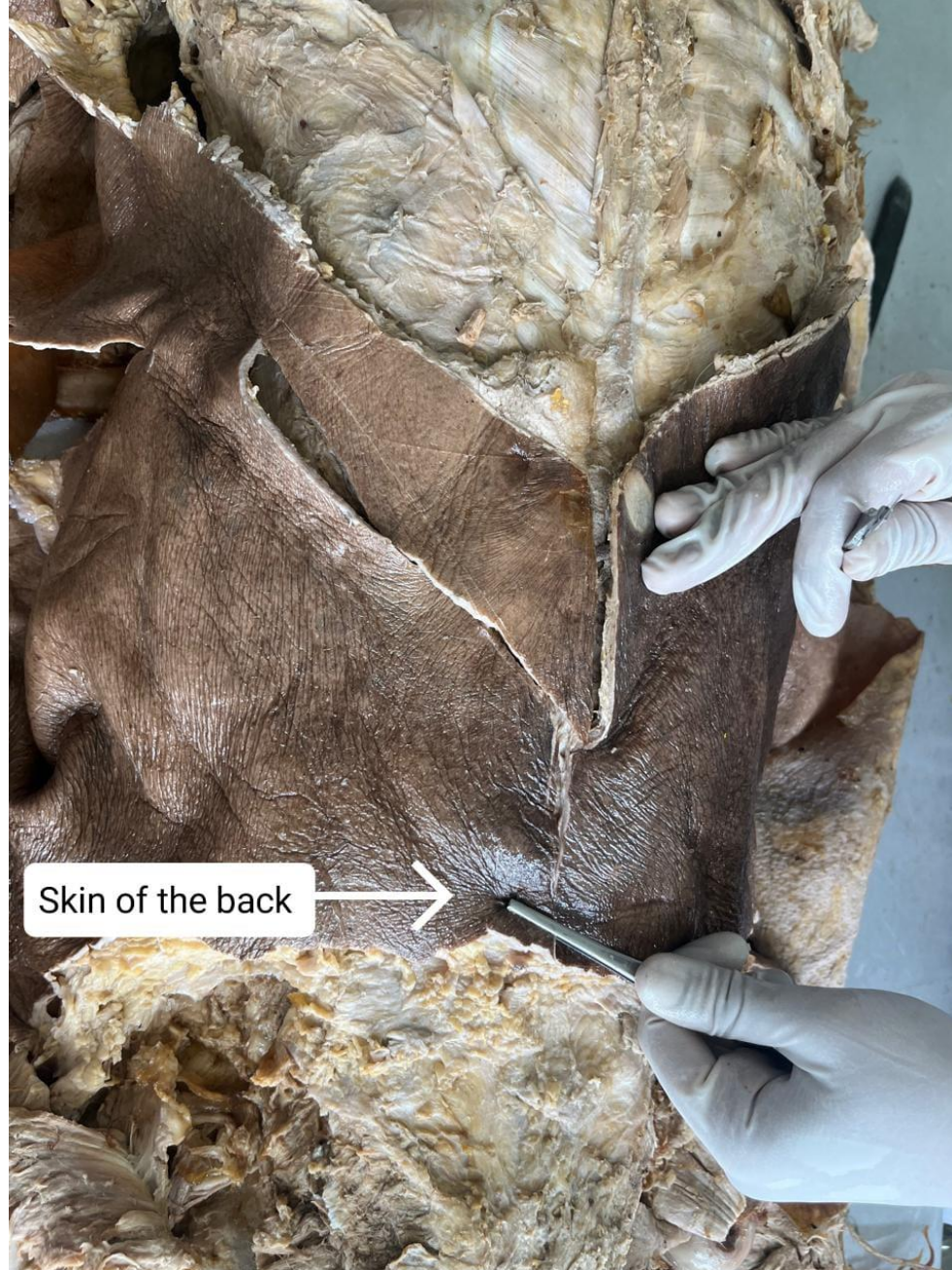-palpate intervertebral space with help of pulp of thumb

-a local anaesthetic is injected into lower back to numb the puncture site before the needle is inserted

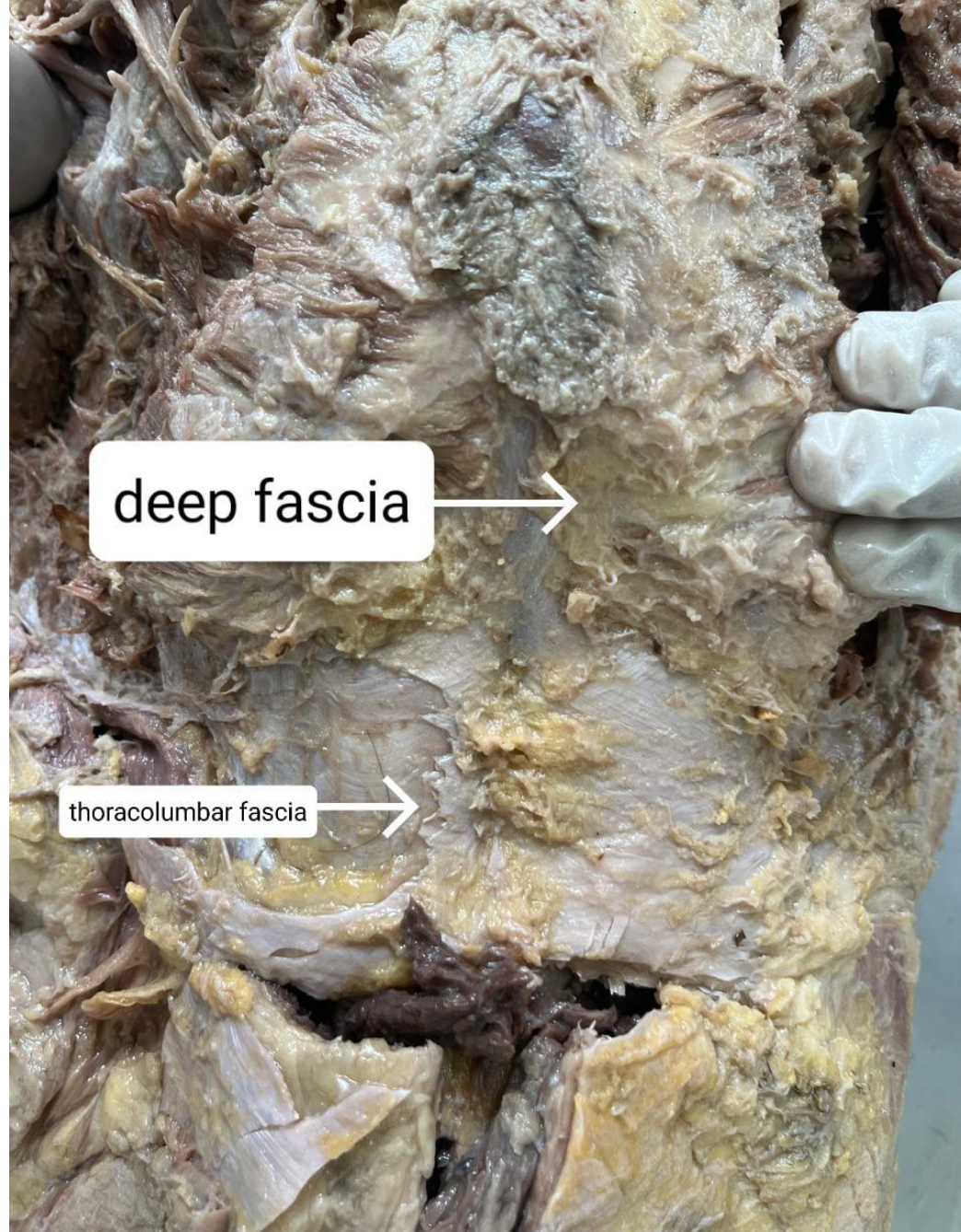
-a thin hollow needle is inserted between the two lower vertebrae(lumbar region),through the spinal membrane(dura)into the spinal canal

-once the needle is in subarachnoid space,small amount of cerebrospinal fluid is withdrawn and the pressure is measured,anaesthetic drug is injected


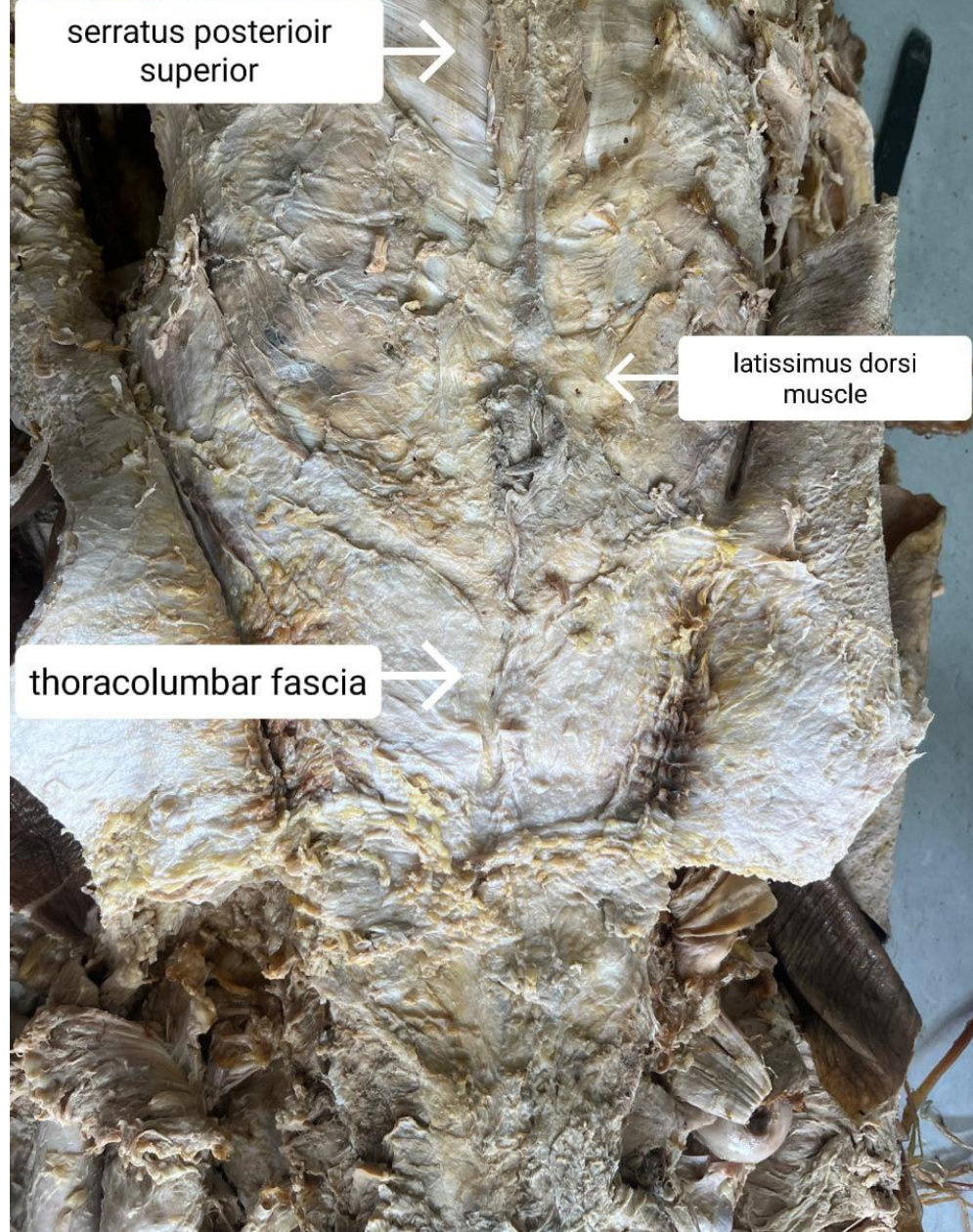




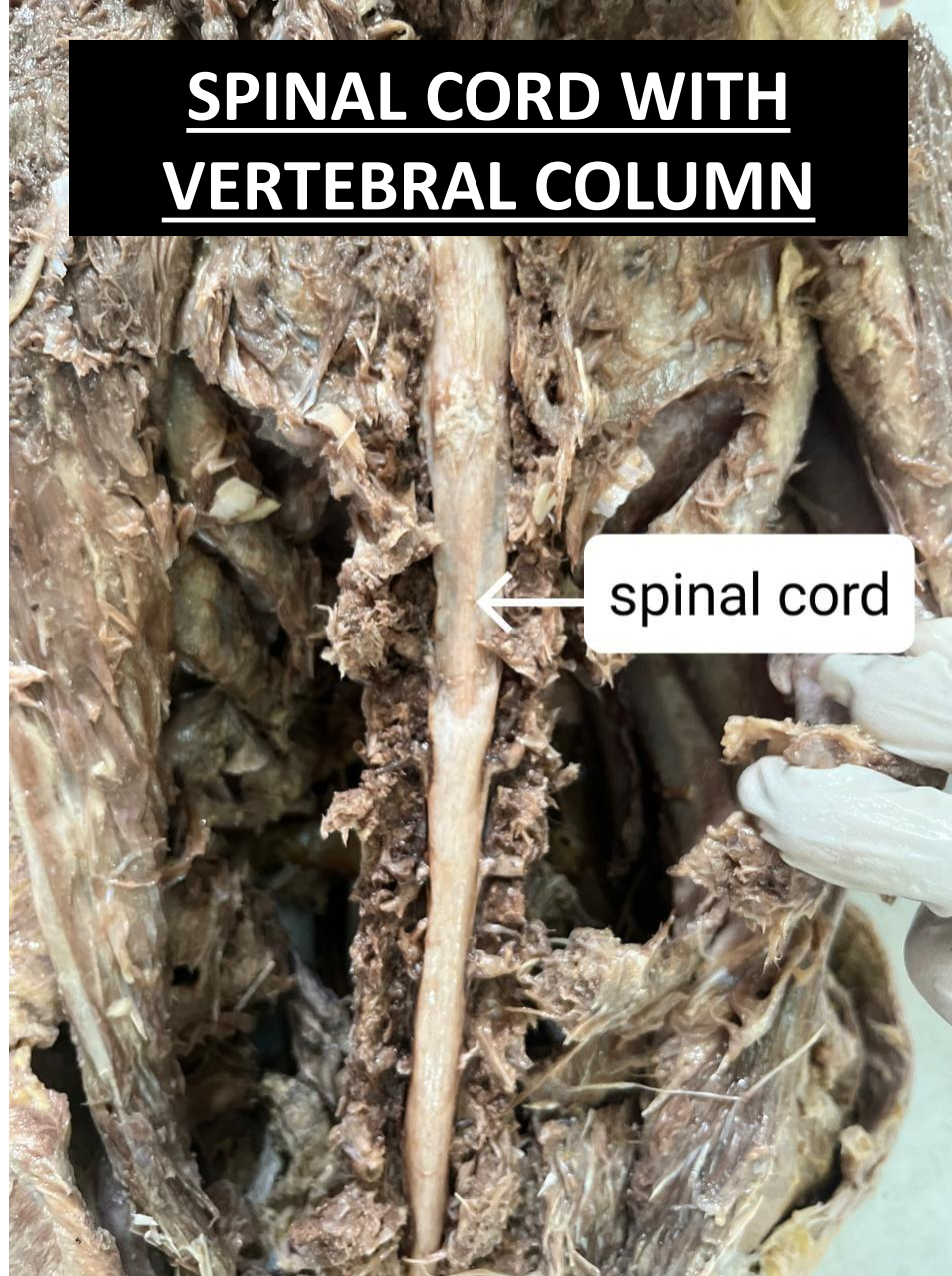






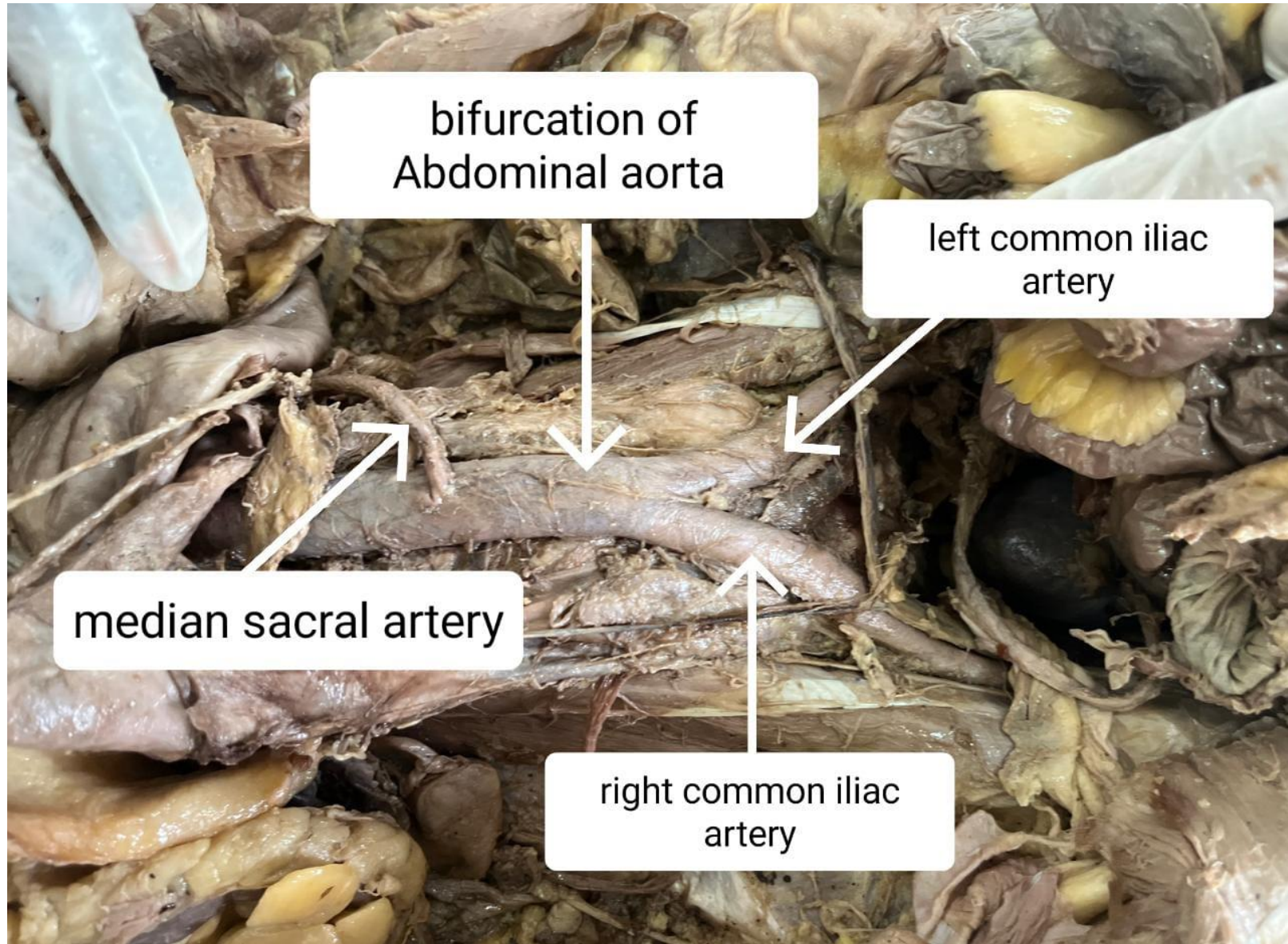



# SPINAL CORD WITH VERTEBRAL COLUMN





# STRUCTURES ANTERIOR TO VERTEBRAL COLUMN





# THANK YOU

MAM's Sumatibhai Shah Ayurved Mahavidyalaya, Hadapsar